



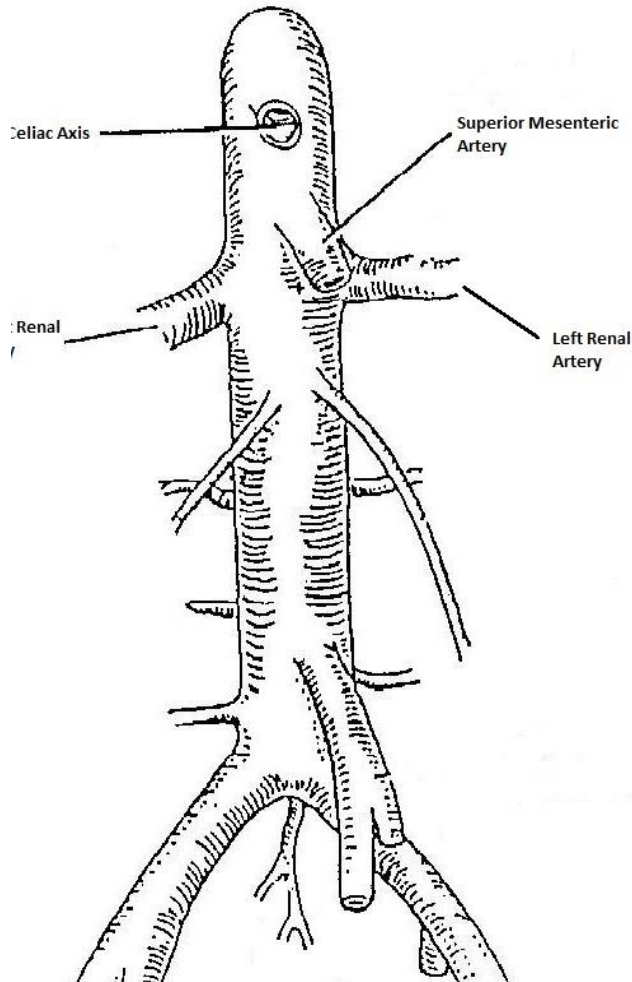
CARDIORISK AAA SCREENING

Patient Name: LEONARD, SHEILA Date: 12-08-2023

DOB: 11/12/1945 Sex: F

Referring Provider: ELIZABETH ANDERSON-HALABUK

Vascular Technician: MICHELE WALTERS



Aorta Prox

2.2 cm Trans X 2.1 cm AP

Aorta Mid

2.0 cm Trans X 1.7 cm AP

Aorta Distal

1.5 cm Trans X 1.5 cm AP

Comments: No Abdominal Aortic Dilatation / Aneurysm was identified in the submitted images. There was a small amount of calcified plaque identified in the Abdominal Aorta.



